

## In Brief

### The Risser Classification: A Classic Tool for the Clinician Treating Adolescent Idiopathic Scoliosis

Jacques H. Hacquebord MD, Seth S. Leopold MD

Published online: 27 April 2012  
© The Association of Bone and Joint Surgeons® 2012

#### History

Joseph C. Risser first described what now is called the Risser sign in 1958 [17]. Risser observed that the state of ossification of the iliac apophysis was associated with the state of a patient's spinal skeletal maturity, a critical piece of information in the management of adolescent scoliosis [17]. His findings developed from work he did with Ferguson in 1936, which showed growth of the spinal column and progression of scoliosis were more rapid in children between 10 and 15 years old than in children between 5 and 10 years [18]. However, the difficulty of evaluating the vertebral growth plates drove him to look for a surrogate that could indicate vertebral growth potential. Risser found the completed excursion and ossification of the iliac apophysis were generally concurrent with that of the vertebral growth plates, and so he concluded, "the attachment of the iliac apophysis has proved to be an excellent physiologic sign to indicate the completion of the vertebral growth" [17].

---

Each author certifies that he or she, or a member of their immediate family, has no commercial associations (eg, consultancies, stock ownership, equity interest, patent/licensing arrangements, etc) that might pose a conflict of interest in connection with the submitted article.

All ICMJE Conflict of Interest Forms for authors and *Clinical Orthopaedics and Related Research* editors and board members are on file with the publication and can be viewed on request.

---

J. H. Hacquebord, S. S. Leopold (✉)  
Department of Orthopaedics and Sports Medicine, University  
of Washington School of Medicine, 1959 NE Pacific Street,  
Box 356500, Seattle, WA 98195, USA  
e-mail: leopold@u.washington.edu

#### Purpose

Adolescent idiopathic scoliosis is relatively common. Depending on the degree and type of curvature, treatment can range from observation to invasive procedures including surgery for correction of spinal deformity and fusion. The more severe the curve, the more likely surgery is to enter the conversation between patient and physician. For curves that are not severe at the time of presentation, the decision regarding whether to operate depends on the surgeon's belief regarding whether the curve will progress as the patient grows. The best predictors of curve progression are growth potential and growth velocity, both of which are functions of skeletal maturity [4, 23]. This parameter guides followup interval, duration of brace treatment, the decision to operate, and timing of surgery. Physicians who treat adolescent idiopathic scoliosis use markers that correlate with skeletal maturity to assist in treatment decisions, including chronologic age, skeletal age, menarchal stage, and stage of development of the iliac crest apophysis (Risser stage) [15]. Among these, the Risser stage perhaps is the most widely used indicator for skeletal maturity.

#### The Risser Staging System

Risser divided the steps of ossification and fusion of the iliac apophysis into six stages (Risser Stages 0–5), with the higher numbers describing advancement toward skeletal maturity. Stage 0 describes an x-ray on which no ossification center is seen in the apophysis, whereas Stage 5 represents complete ossification and fusion of the iliac apophysis. Two slightly different versions of the Risser system are in use; the differences concern Stages 2 to 4 [2, 3, 13].

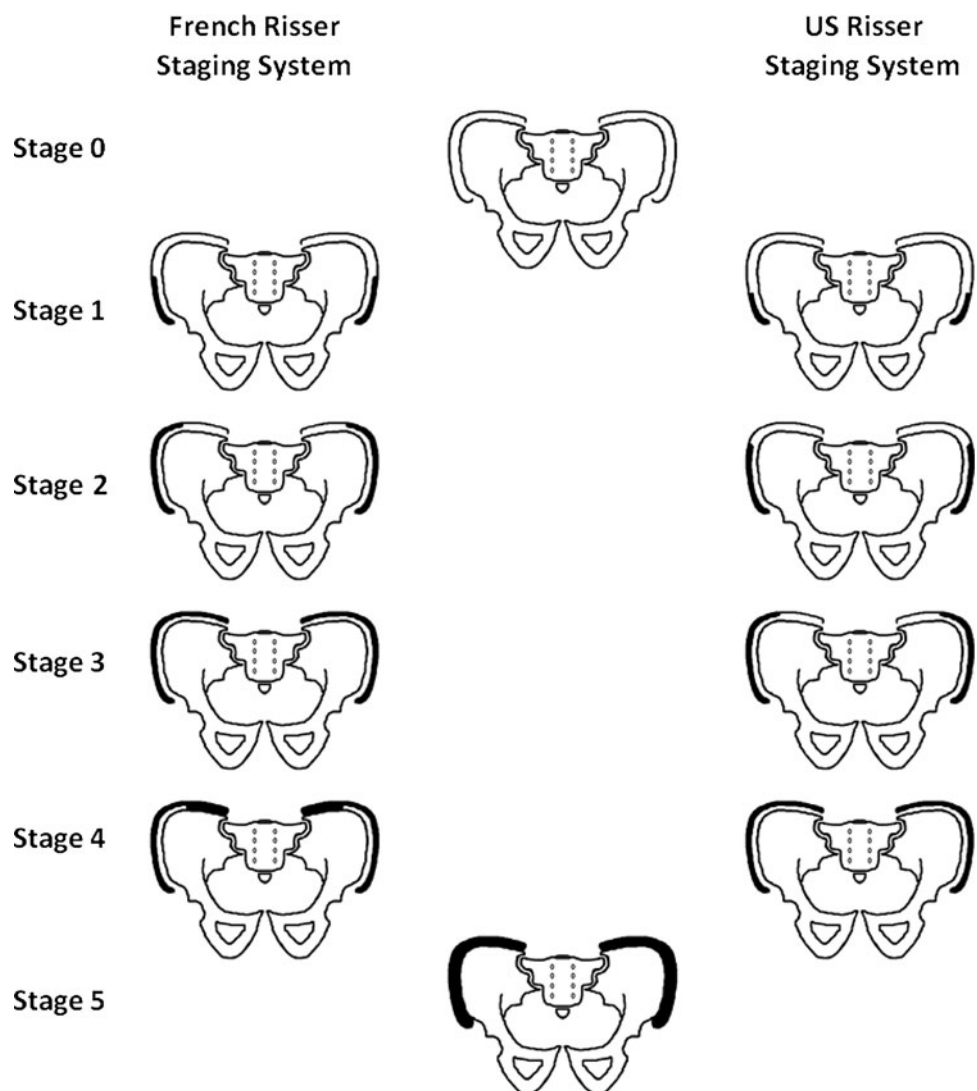
The United States Risser staging system divides the excursion of the apophysis into quarters of the iliac crest beginning anterolaterally and progressing posteromedially (Fig. 1), whereas the French Risser staging system divides the excursion of the apophysis into thirds (Stages 1–3), with Stage 4 representing complete ossification and initiation of apophyseal fusion (Fig. 1). It is important to be aware of this difference when communicating Risser stages, as the French version will tend to stage apophyseal fusion by one less stage than the US system [2].

### Confirmation and Validation

Since its introduction in 1958, the Risser stage has been used extensively but, importantly (unlike many other radiographic signs in common clinical use), it also has been

validated. More than 20 years ago, Goldberg et al. found acceptable interobserver reliability for the Risser stage ( $Kappa = 0.8$ ) [8]. In a larger and more recent study, Reem et al. reconfirmed this finding and concluded the Risser stage is “a reliable radiographic parameter when evaluating the growth potential in children with scoliosis” [16]. Sanders et al. found the Risser stage was one of several valid approaches to determining skeletal maturity (the others being the Tanner-Whitehouse-III, Greulich and Pyle, and Oxford methods), and that the Risser stage correlated with peak curve progression [19]. In addition to acceptable interobserver reliability and clinical utility, the Risser stage also reflects the local biology with some precision; one study found the histologic stage of iliac apophyseal chondrocytes also was inversely correlated with Risser stage, and further confirms the Risser stage as a useful indicator of growth potential in adolescent idiopathic scoliosis [22].

**Fig. 1** The French and US Risser staging systems have six stages. Stage 0 in the US and French systems is defined as no ossification of the apophysis. In the French system, ossification of the iliac wing is divided into thirds and represents Stages 1, 2, and 3. Stage 4 defines the period when the apophysis commences fusion to the iliac wing posteriorly, whereas Stage 5 is when fusion of the apophysis to the iliac wing is complete. Ossification of the apophysis in the US system is divided into quarters, defining the first four stages (1, 2, 3, 4). Risser Stage 5 describes the period when the ossified apophysis fuses to the iliac wing.



## Limitations

Ossification of the iliac apophysis typically progresses along the iliac crest from anterolaterally to posteromedially. However, anomalous ossification progression of the iliac apophysis does occur, and sometimes can complicate accurate Risser staging [21]. Radiographic technique also may be important; evaluation of the apophyseal ossification excursion from anterolaterally to posteromedially is more difficult when viewing the iliac crest on posteroanterior films because of the overlapping ilium [9]. Izumi actually found distortion on the PA films to be so significant that he concluded, "...the appearance of the iliac apophysis on posteroanterior radiograph cannot be used as a reliable indicator of skeletal maturity [9]. To address this issue, Shuren et al. recommend performing bending AP pelvis films (recumbent AP oblique bending views) to more accurately determine Risser stage since this portrays "the entire excursion of the iliac apophysis, whereas in the posteroanterior views, the ilium obscures the apophysis" [21]. Reem et al. also stated that reliability can be improved when the Risser stage is assessed on full pelvis radiographs allowing for determining closure of the triradiate cartilage, fusion of the greater trochanteric apophysis, and ossification of the lateral acetabulum, these being particularly useful when distinguishing between Risser Stages 0 and 5 [16].

Another weakness of the Risser staging system is related to the fact that greatest curve progression typically occurs concomitantly with greatest peak height velocity [11, 23]. Little et al. showed that peak height velocity and  $\frac{2}{3}$  of pubertal growth occurs before the first signs of iliac apophysis ossification, thus before Risser staging becomes useful [11]. Furthermore, Risser Stage 4 has commonly been thought of as a point at which there is cessation of curve progression, thus justifying longer intervals between observation and waning concern for scoliotic curve progression. However, there is strong evidence that Risser Stage 4 is not an accurate measure for cessation of curve progression and that trunk growth continues until Risser Stage 5 [1, 9, 14]. This has been verified by histologic studies that show substantial vertebral end-plate growth persists in Risser Stage 4 and that Stage 5 was the only accurate indicator of vertebral growth cessation [12]. This is especially true in adolescent boys with idiopathic scoliosis where the natural history of idiopathic scoliosis differs from that in girls [4, 10]. Karol et al. showed that boys commonly have late onset of scoliosis and delayed curve progression often in Risser Stage 5, decreasing the usefulness of the staging system in boys [10].

Furthermore, Sanders et al. concluded the Risser stage was poorly correlated with the period of greatest curve progression (R value, 0.60), whereas the newer Digital Skeletal Age (Tanner-Whitehouse-III RUS score) better

correlated with curve progression [19, 20]. The Tanner-Whitehouse method can be difficult and time consuming to use [6] with the Digital Skeletal Age also being cumbersome to obtain and arguably more appropriate as a research tool [20]. To improve the correlation of curve progression and Risser staging system, Nault et al. proposed a modification to the Risser system where Stage 0 was divided into two groups (open triradiate cartilage and closed triradiate cartilage) [13]. They found this improved the predictive power of the staging system to determine the initiation of curve progression and better correlated with Digital Skeletal Age [13]. Dimeglio also proposed that Risser Stage 0 be subdivided into open triradiate cartilage and closed triradiate cartilage in order to make Risser stage 0 more useful [6]. Derived from the Sauvegrain method that assesses skeletal age by using the development of elbow ossification centers, Dimeglio et al. proposed a simplified system that evaluates morphologic development of the olecranon to determine the accelerating growth phase [7]. To make Risser Stage 0 more useful, this simplified olecranon method has been validated and proposed to be used in conjunction with patients with Risser Stage 0 disease to determine skeletal age and peak height velocity [5].

Even so, the Risser classification remains one of a relatively small number of orthopaedic classifications that is reliable, clinically useful, and reflects the local biology; for these reasons and for its relative simplicity and familiarity to pediatric orthopaedic surgeons, the Risser system remains in wide use.

## Conclusions/Uses

The Risser staging system is a reliable and useful tool, but as shown above, one that is best used in a broader context, along with other tools that help the clinician to gauge skeletal maturity, particularly growth potential. Proposed modifications to the Risser staging system have been made to have it more closely correlate with Digital Skeletal Age scores, which have been shown to represent periods of greatest curvature acceleration [13, 19, 20]. To improve the prediction of curve progression, the Risser stage should be used in conjunction with other tools such as skeletal age, chronologic age, and time since menarche in females. In particular, clinicians should remain cognizant of the two versions of the Risser staging system and that vertebral growth can persist even at Risser Stage 4.

## References

1. Anderson M, Hwang SC, Green WT. Growth of the normal trunk in boys and girls during the second decade of life; related to age,

- maturity, and ossification of the iliac epiphyses. *J Bone Joint Surg Am.* 1965;47:1554–1564.
2. Bitan FD, Veliskakis KP, Campbell BC. Differences in the Risser grading systems in the United States and France. *Clin Orthop Relat Res.* 2005;436:190–195.
  3. Brand RA. 50 years ago in CORR: the iliac apophysis: an invaluable sign in the management of scoliosis Joseph C. Risser MD CORR 1958;11:111–119. *Clin Orthop Relat Res.* 2008;466:1516–1517.
  4. Bunnell WP. The natural history of idiopathic scoliosis before skeletal maturity. *Spine (Phila Pa 1976).* 1986;11:773–776.
  5. Charles YP, Diméglio A, Canavese F, Daures JP. Skeletal age assessment from the olecranon for idiopathic scoliosis at Risser grade 0. *J Bone Joint Surg Am.* 2007;89:2737–2744.
  6. Dimeglio A. Growth in pediatric orthopaedics. *J Pediatr Orthop.* 2001;21:549–555.
  7. Diméglio A, Charles YP, Daures JP, de Rosa V, Kaboré B. Accuracy of the Sauvegrain method in determining skeletal age during puberty. *J Bone Joint Surg Am.* 2005;87:1689–1696.
  8. Goldberg MS, Poitras B, Mayo NE, Labelle H, Bourassa R, Cloutier R. Observer variation in assessing spinal curvature and skeletal development in adolescent idiopathic scoliosis. *Spine (Phila Pa 1976).* 1988;13:1371–1377.
  9. Izumi Y. The accuracy of Risser staging. *Spine (Phila Pa 1976).* 1995;20:1868–1871.
  10. Karol LA, Johnston CE 2nd, Browne RH, Madison M. Progression of the curve in boys who have idiopathic scoliosis. *J Bone Joint Surg Am.* 1993;75:1804–1810.
  11. Little DG, Song KM, Katz D, Herring JA. Relationship of peak height velocity to other maturity indicators in idiopathic scoliosis in girls. *J Bone Joint Surg Am.* 2000;82:685–693.
  12. Little DG, Sussman MD. The Risser sign: a critical analysis. *J Pediatr Orthop.* 1994;14:569–575.
  13. Nault ML, Parent S, Phan P, Roy-Beaudry M, Labelle H, Rivard M. A modified Risser grading system predicts the curve acceleration phase of female adolescent idiopathic scoliosis. *J Bone Joint Surg Am.* 2010;92:1073–1081.
  14. Noordeen MH, Haddad FS, Edgar MA, Pringle J. Spinal growth and a histologic evaluation of the Risser grade in idiopathic scoliosis. *Spine (Phila Pa 1976).* 1999;24:535–538
  15. Peterson LE, Nachemson AL. Prediction of progression of the curve in girls who have adolescent idiopathic scoliosis of moderate severity: logistic regression analysis based on data from The Brace Study of the Scoliosis Research Society. *J Bone Joint Surg Am.* 1995;77:823–827.
  16. Reem J, Carney J, Stanley M, Cassidy J. Risser sign inter-rater and intra-rater agreement: is the Risser sign reliable? *Skeletal Radiol.* 2009;38:371–375.
  17. Risser JC. The iliac apophysis; an invaluable sign in the management of scoliosis. *Clin Orthop.* 1958;11:111–119.
  18. Risser JC, Ferguson AB. Scoliosis: its prognosis. *J Bone Joint Surg.* 1936;18:667–670.
  19. Sanders JO, Browne RH, McConnell SJ, Margraf SA, Cooney TE, Finegold DN. Maturity assessment and curve progression in girls with idiopathic scoliosis. *J Bone Joint Surg Am.* 2007;89:64–73.
  20. Sanders JO, Khoury JG, Kishan S, Browne RH, Mooney JF 3rd, Arnold KD, McConnell SJ, Bauman JA, Finegold DN. Predicting scoliosis progression from skeletal maturity: a simplified classification during adolescence. *J Bone Joint Surg Am.* 2008;90:540–553.
  21. Shuren N, Kasser JR, Emans JB, Rand F. Reevaluation of the use of the Risser sign in idiopathic scoliosis. *Spine (Phila Pa 1976).* 1992;17:359–361.
  22. Wang WW, Xia CW, Zhu F, Zhu ZZ, Wang B, Wang SF, Yeung BH, Lee SK, Cheng JC, Qiu Y. Correlation of Risser sign, radiographs of hand and wrist with the histological grade of iliac crest apophysis in girls with adolescent idiopathic scoliosis. *Spine (Phila Pa 1976).* 2009;34:1849–1854.
  23. Ylikoski M. Growth and progression of adolescent idiopathic scoliosis in girls. *J Pediatr Orthop B.* 2005;14:320–324.